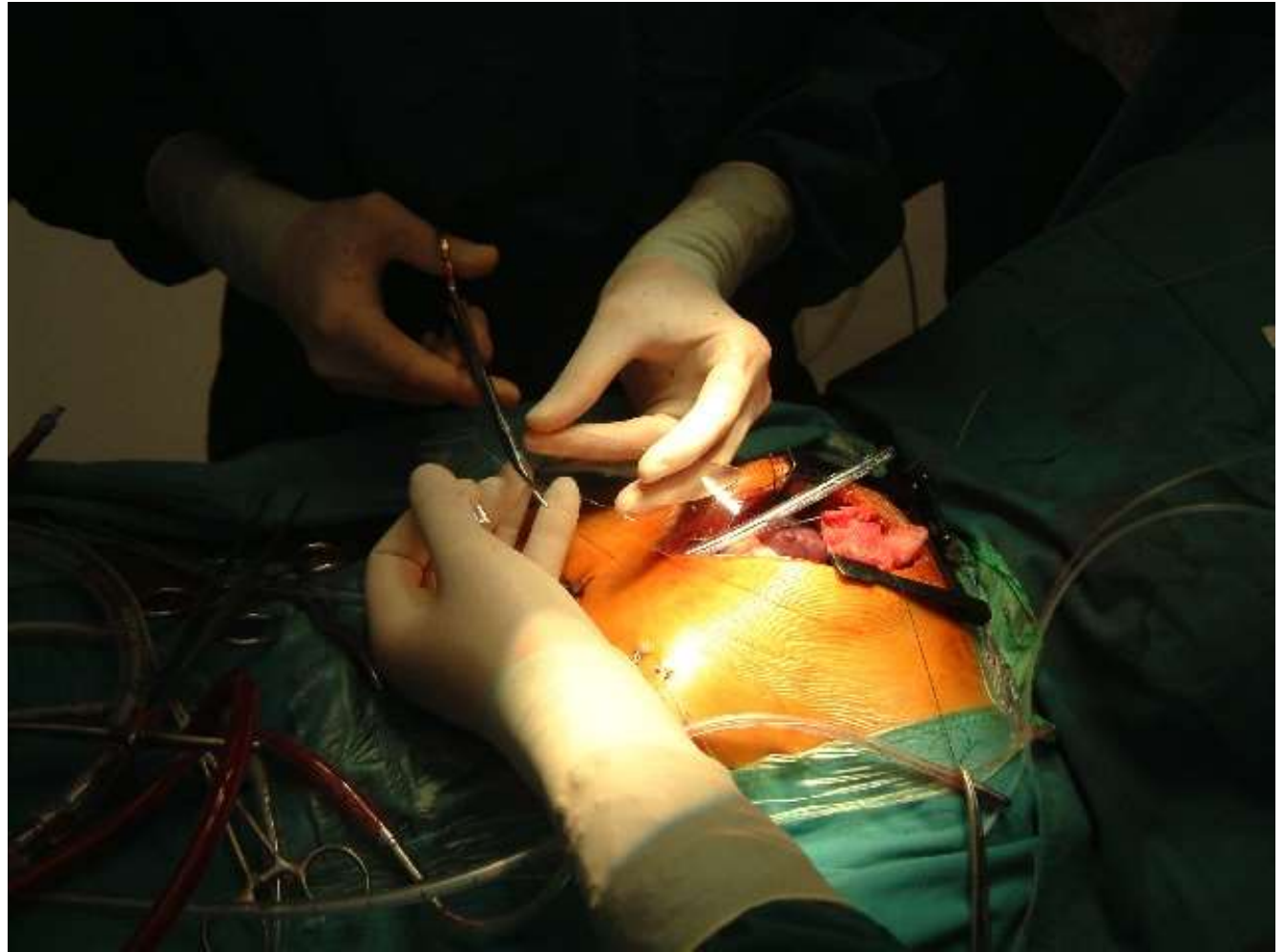


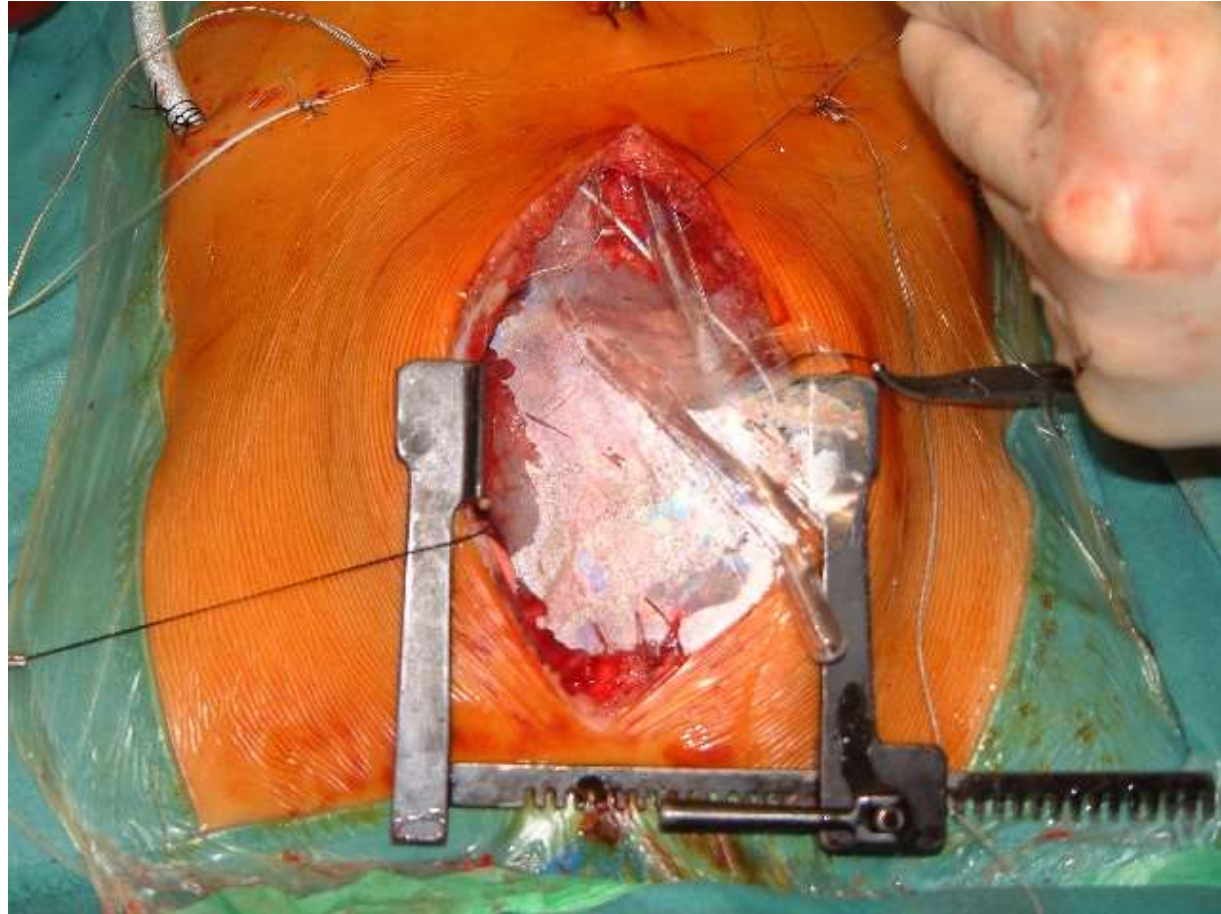
Case Study: Pericardial Reconstruction in Pediatric Surgery

Pictures at courtesy of B. Asfour, MD
PhD, German Pediatric Heart Center
(Dt. Kinderherzzentrum), St. Augustin,
Germany

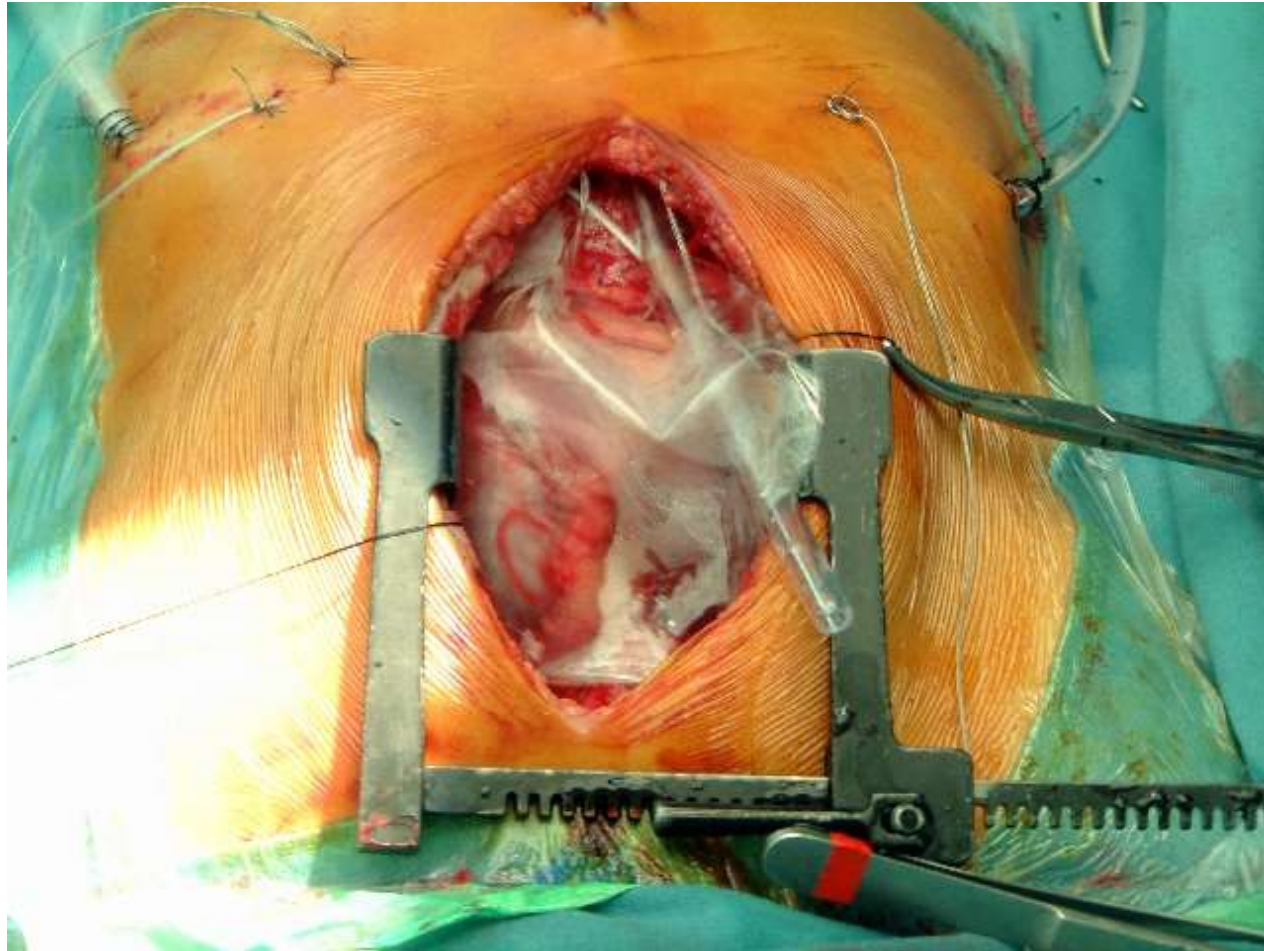
Trimming of CardioWrap to size



Retrosternal placement of the sheet and attachment to the residual pericardium with single sutures.



The drains are placed underneath the sheet. One or two small fenestrations are cut into the sheet to allow and promote drainage.



CardioWrap covering the secured pericardium

