BARIATRIC TIMES Presents

Clinical Insights in Bariatric Surgery

Volume 1, Number 1 January/February 2005

Management of Tissue Attachment Through the Use of SurgiWrap® Bioresorbable Sheets

by Noel N. Williams, MD, MCh, FRCSI, FRCS (Gen)

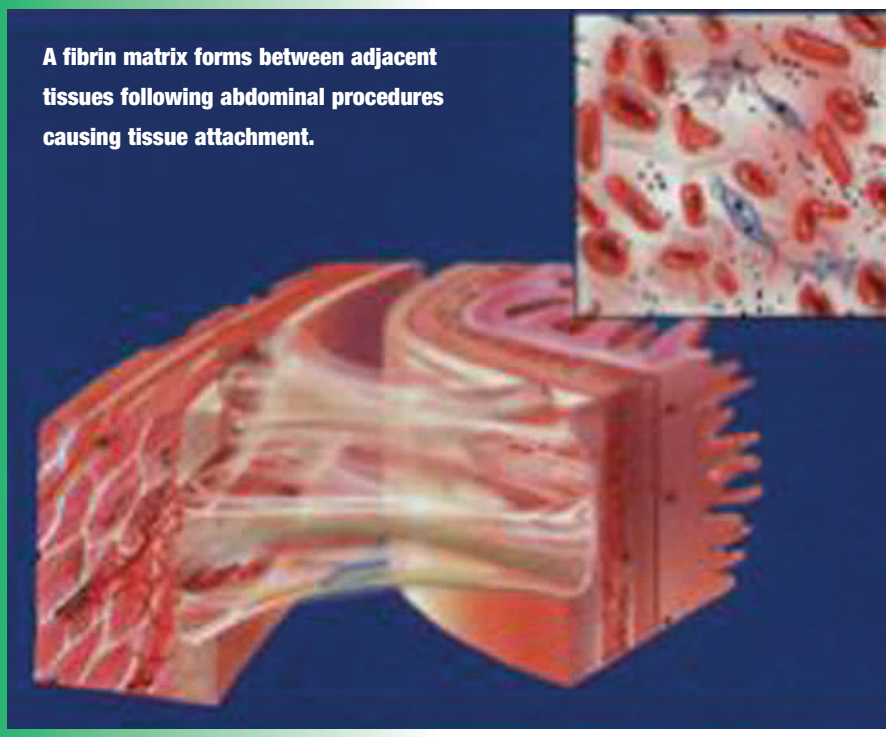

A fibrin matrix forms between adjacent tissues following abdominal procedures causing tissue attachment.

Dr. Williams is the Director of the Bariatric Program, Department of Surgery, at the University of Pennsylvania in Philadelphia, Pennsylvania.

The number of bariatric procedures has grown exponentially over the past few years. In the year 2000, 40,000 procedures were performed; 80,000 were performed in 2002; 100,000 procedures were performed in 2003;[1] and it is estimated that 140,000 bariatric procedures were performed in 2004.[2] Bariatric surgery, including Roux-en-Y gastric bypass, gastric restrictive procedures, laparoscopic adjustable gastric banding, and bilio-pancreatic diversion, provides effective weight loss with the added benefit of the majority of patients achieving improvement or complete resolution of hypertension,

TABLE 1. TYPES (GRADING) OF ATTACHMENTS	
Type I	Loose and filmy: Removed by blunt dissection (Figure 1)
Type II	Thick attachments: Sharp dissection may be required for removal
Type III	Attachment to contiguous organs: Significant sharp dissection may be required for removal (Figure 2)
Type IV	Total fusion with intestine; Injury is inevitable.

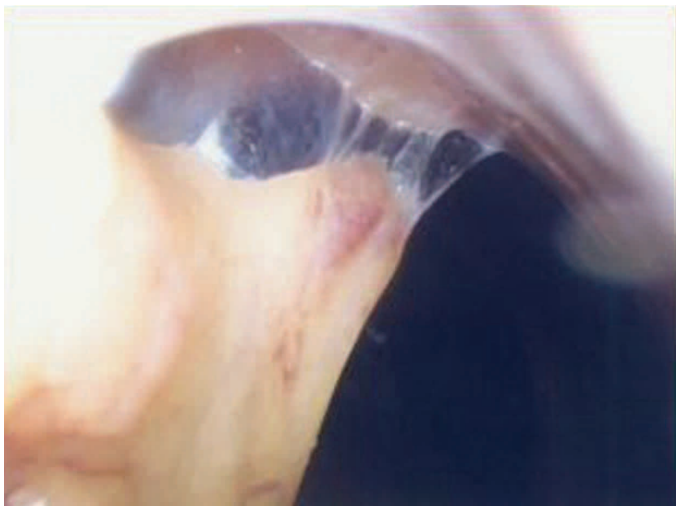

FIGURE 1. Loose filmy primary tissue attachments

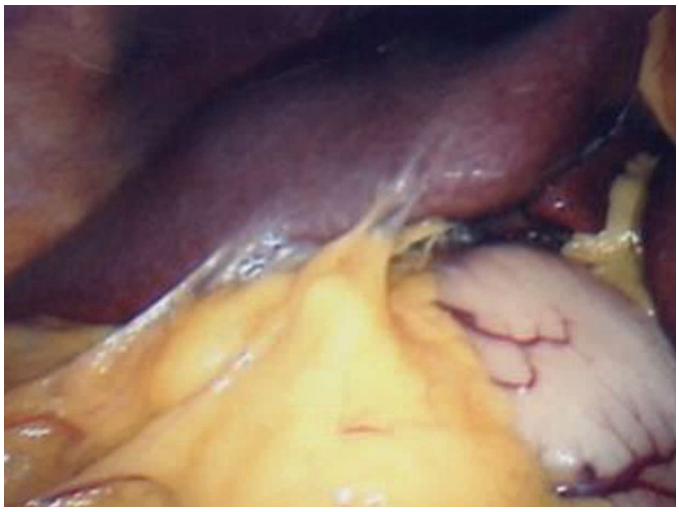

FIGURE 2. Dense fibrous tissue attachment between the duodenum and the gallbladder fossa following cholecystectomy

hyperlipidemia, obstructive sleep apnea, and diabetes.[3] The mortality rates range between 0.1 and 0.5 percent for the more popular procedures, showing that bariatic surgery is not only effective, but safe.[3] As with any abdominal surgery, however, a problem often encountered following weight loss surgical procedures is the formation of dense fibrous tissues. What are tissue attachments? Why do they form? How can they be managed? This article will answer these important questions.

TYPES OF BARIATRIC PROCEDURES

The gold standard of weight loss surgery is the Roux-en-Y gastric bypass. Briefly, this operation consists of a restrictive component, the formation of a small gastric pouch, and a malabsorbtive component, the jejeunal bypass and gastro-jejeunal amastomosis. This procedure can be performed by the open method or by the laparoscopic technique. The majority of patients undergoing bariatric surgery have this procedure, but the laparoscopic adjustable gastric band (restrictive operation) is gaining in popularity.

Gastric restrictive procedures include vertical banded gastroplasty (open and laparoscopic), laparoscopic adjustable gastric banding, and the laparoscopic sleeve gastrectomy. There is significant data to suggest that the laparoscopic adjustable gastric band is a safe and effective procedure for weight loss, and the numbers of these procedures being performed is on the increase. The vertical banded gastroplasty and sleeve gastrectomy procedures are becoming popular as bridging procedures towards definitive surgery in the "super obese" population.

FIBRINOUS BAND FORMATION

As in any abdominal surgical procedure, a problem that can occur following weight loss surgery is unwanted tissue attachment. These

attachments occur when fibrinous bands form and connect intra-abdominal tissue surfaces that are normally separated from one another. These post-surgical attachments will form in more than 90 percent of abdominal and pelvic procedures. The consequences of unwanted formations are intestinal obstruction, infertility, chronic abdominal pain, and difficulty with re-operative elective surgery. In the case of bariatric surgery and, specifically, in the second operation following either a sleeve gastrectomy or vertical banded gastroplasty, it is desirable to have an operative field free of attachments to facilitate the procedure. An excess of attachments in this setting makes the second procedure more difficult and potentially more time consuming. See Table 1 and Figures 1 and 2 for the types and grading of attachments.

MANAGING SOFT TISSUE ATTACHMENT

There are many techniques that aid in the management of post-operative attachments. These include careful hemostasis and tissue handling, proper wound irrigation, prevention of ischemia, carefully controlled or prevention of infection, and elimination of any foreign bodies in the wounds. It is important to incorporate all of these techniques to decrease the incidence of attachments.

Another important method that aids in the management of unwanted tissue attachment is to separate the surfaces using a physical barrier. SurgiWrap® MAST Bioresorbable Sheet (Mast BioSurgery, San Diego, California), a sheet made from polylactic acid (specifically 70:30 Poly[L-lactide-co-D,L-lactide]), has been specifically engineered to be used between abdominal tissues to separate the surfaces during and following surgical procedures. Polylactic acid (PLA) has been used in the medical device industry for over 30 years. The 70:30 co-

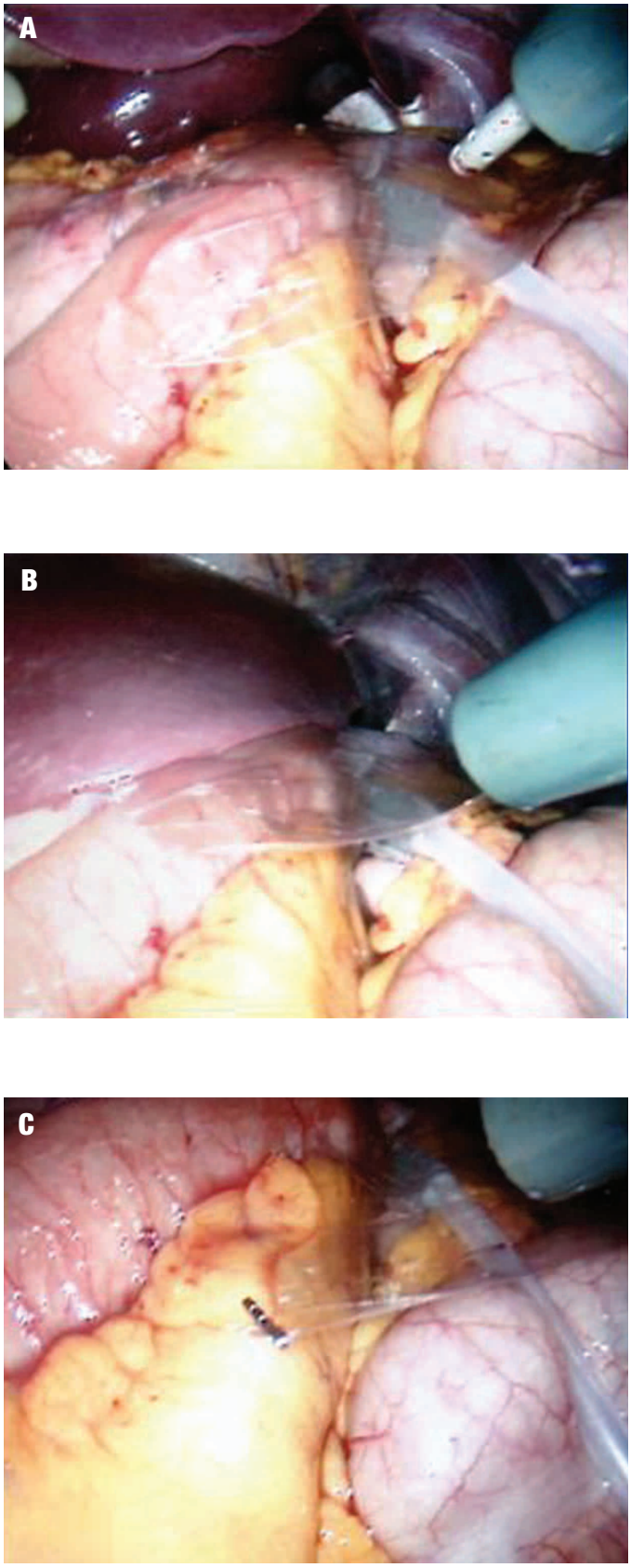

FIGURES 3A–C. Placement of the SurgiWrap and fixation with a surgical clip during laparoscopic gastric bypass

polymer used in SurgiWrap combines high strength with optimal resorption, which occurs after the surgical site is completely healed. The benefit of SurgiWrap is its ability to act as a physical barrier between adjacent tissues and minimize the attachment to the device when in direct contact with the viscera. SurgiWrap has been used with open abdominal surgery, gastrectomy, cholecystectomy, small bowel resection, colonic surgery, liver resection, pancreatic surgery, and gynecological pelvic surgery.

SurgiWrap is not biochemically active. Degradation is by hydrolytic scission or bulk hydrolysis. Metabolism occurs in the liver through the tricarboxylic acid cycle (Krebs cycle). The final end products are CO_2 and H_2O.

The clinical advantages of SurgiWrap are its ease of use; no product fragmentation at time of surgery; no increased risk of host inflammatory reaction; physical presence throughout the healing cycle; and minimization of soft tissue attachment when in direct contact with the device.

SURGIWRAP APPLICATION

SurgiWrap can be used in general surgery and can be applied laparoscopically. It can be rolled and inserted through a 10mm port after which it reverts to its original shape. Once in the abdominal cavity, it is then placed in the desired location and fixed in place using a clip or suture (Figures 3A–C). Specifically relating to bariatric surgery, it is recommended for use in all patients who are undergoing a staged procedure with either a vertical banded gastroplasty or a sleeve gastrectomy. In addition, the author uses SurgiWrap in all laparoscopic gastric bypass cases and with the laparoscopic adjustable gastric band.

REFERENCES

1. Elliot VS. Bariatric surgery patients need care for a lifetime. American Medical News. Available at www.ama-assn.org/amednews/2004/06/28/hlsa0628.htm Accessed on January 13, 2005.
2. Steinbrook R. Surgery for severe obesity. *N Engl J Med* 2004;350(11):1075–9.
3. Buchwald H, Avidor Y, Braunwald E, et al. Bariatric surgery: A systematic review and meta-analysis. *J Am Med Assoc* 2004;292(14):1724–1737.

A Matrix Medical Communications Publication
4975 West Chester Pike
Suite 201, PO Box 445
Edgemont, PA 19028-0445

This month's *Clinical Insights in Bariatric Surgery* was sponsored by MAST BioSurgery, San Diego, California.